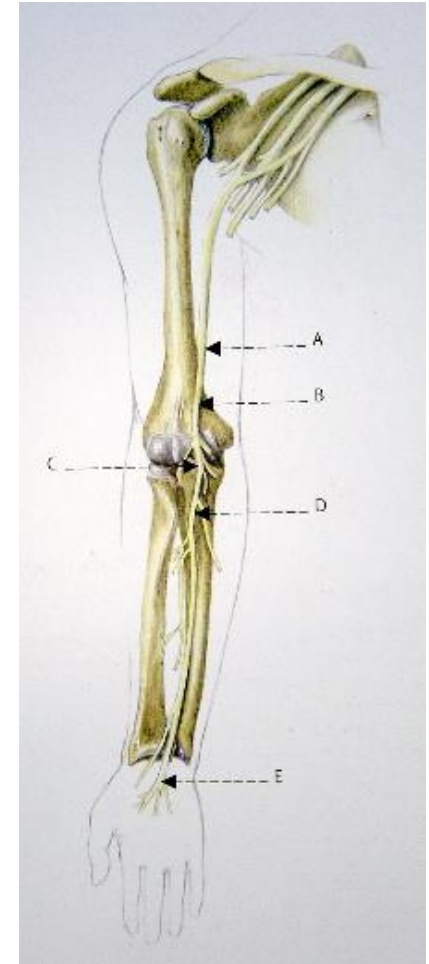


Proximal median nerve entrapment

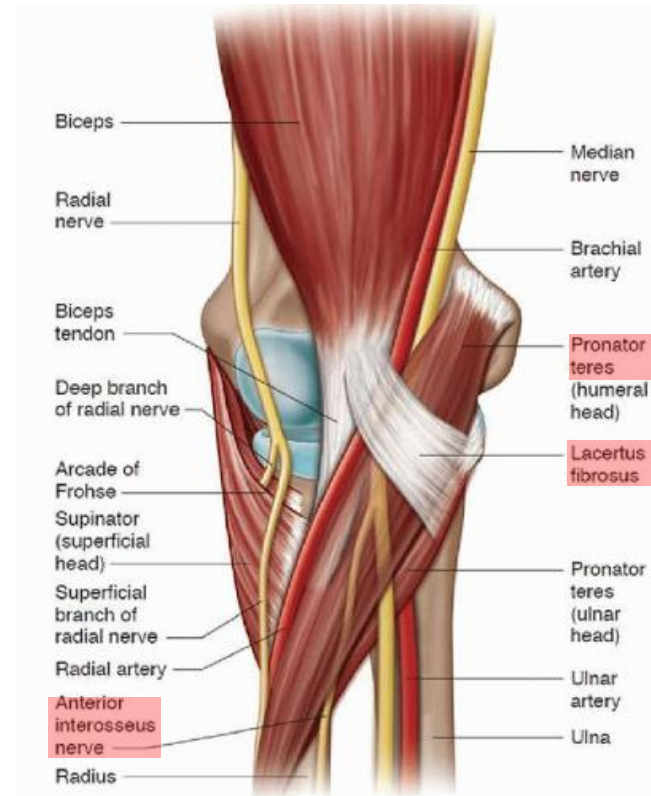
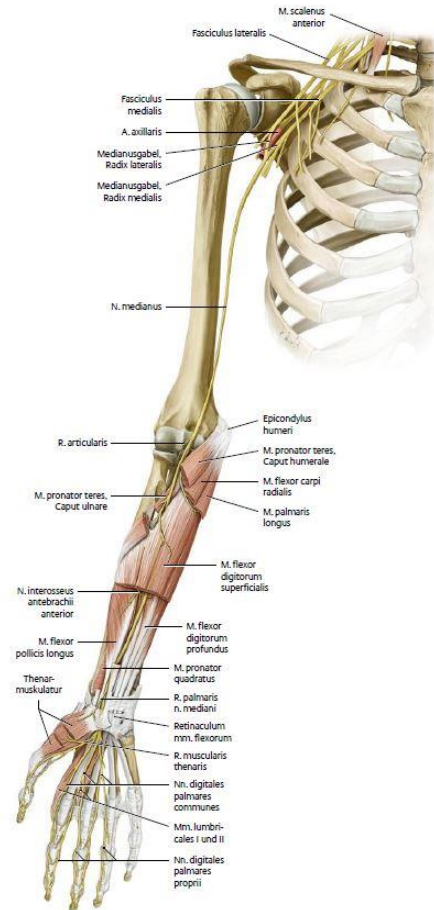
Ramon Büchel

Regions of entrapment

- Struthers` - ligament
- Lacertus fibrosus
- Pronator teres muscle
- FDS-arcade
- Carpal tunnel



Median nerve - anatomy



Median nerve - anatomy

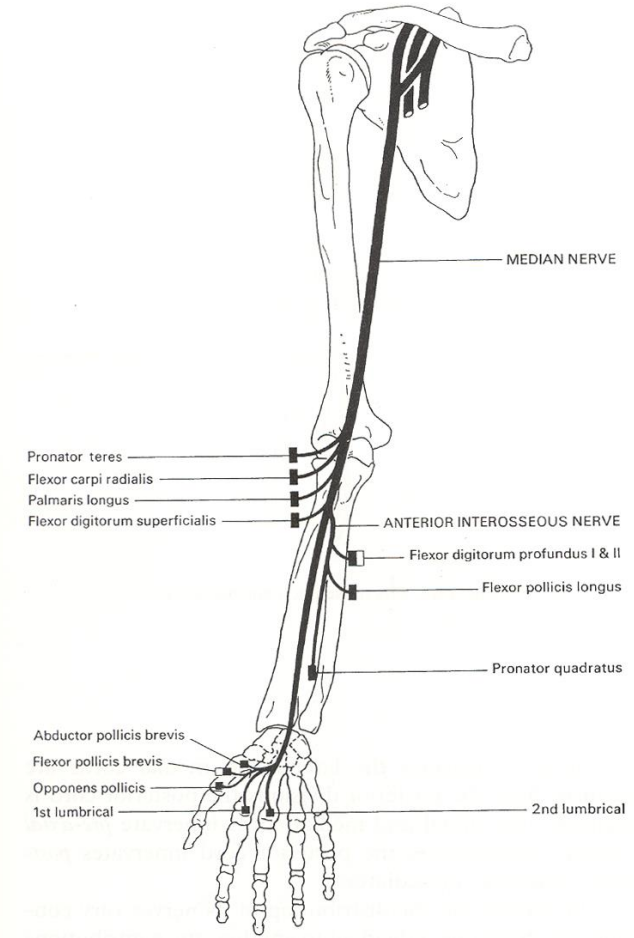
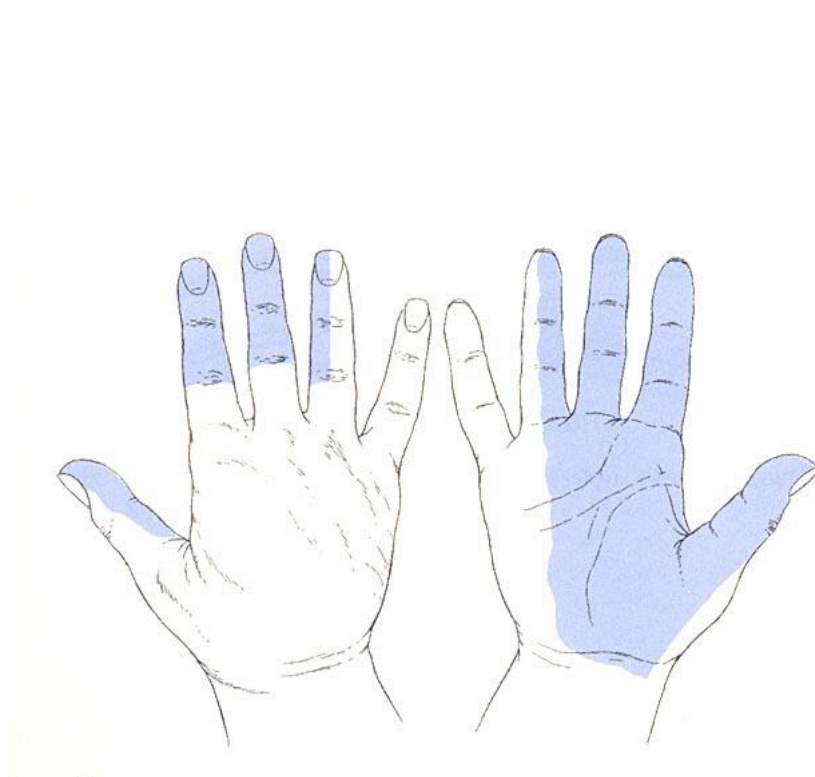
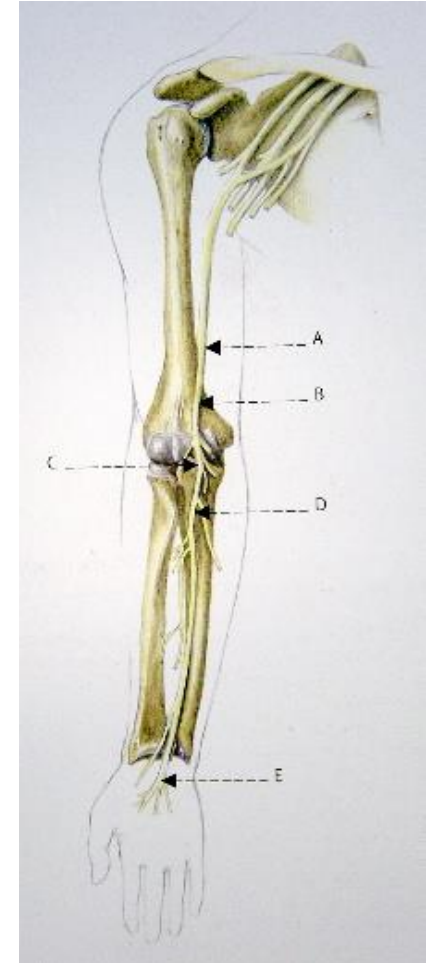


Fig. 1.12 The median nerve.

Regions of entrapment

- Struthers` - ligament
- **Lacertus fibrosus**
- **Pronator teres muscle**
- **FDS-arcade**
- Carpal tunnel



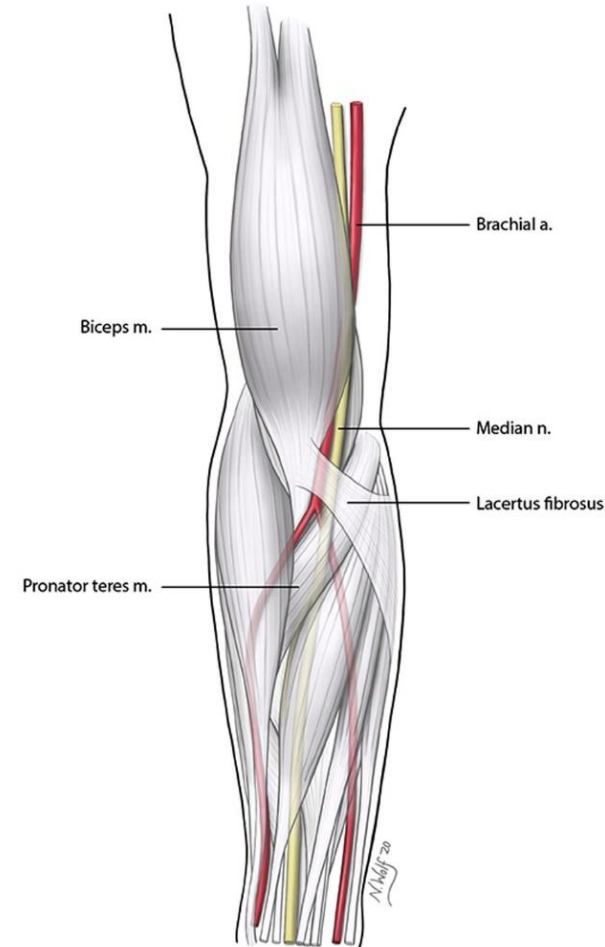
Proximal median nerve entrapment?

- CTS symptoms and....
- R. palmaris!
- Loss of strength!
- Pain at elbow!



Proximal median nerve entrapment

- Rare
- Mostly clinical diagnosis
- No reliable diagnostic
- Patient history:
 - Paraesthesia and pain
 - Impaired dexterity (coordination)
 - Loss of strength



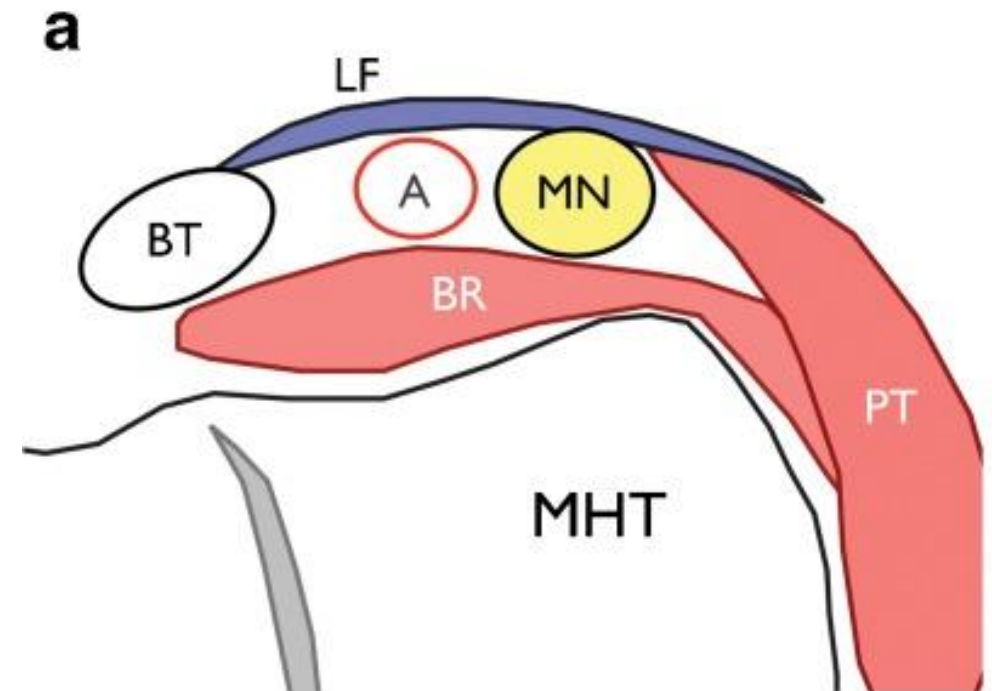
Lacertus syndrome

Definition

- Entrapment of median nerve by lacertus fibrosus

Patient history

- Paraesthesia and pain (rare)
- Problems with the fine finger movements (coordination)
- Loss of strength



Lacertus syndrome – physical examination

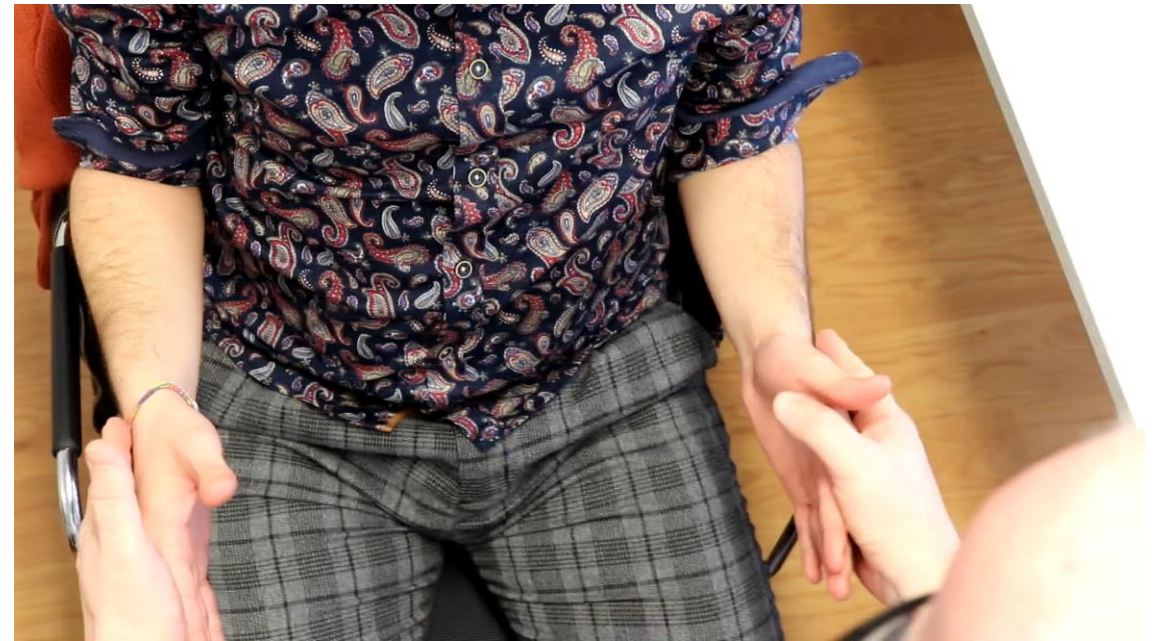Trias (Hagert 2013)

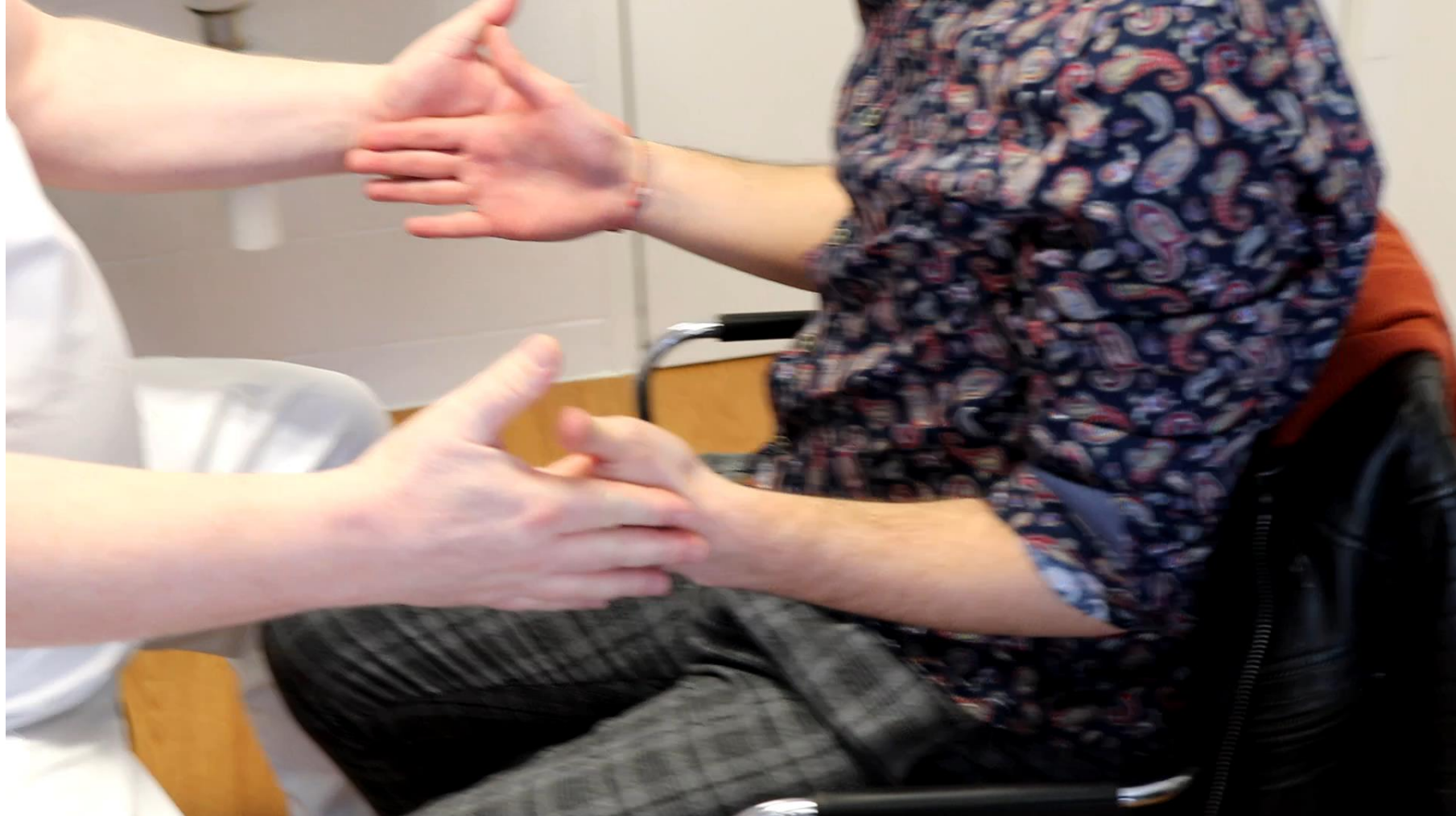1. Strength of FCR, FPL und FDP2 («key und tip pinch strength»)
2. Positive scratch-collapse-test
3. Tenderness on palpation



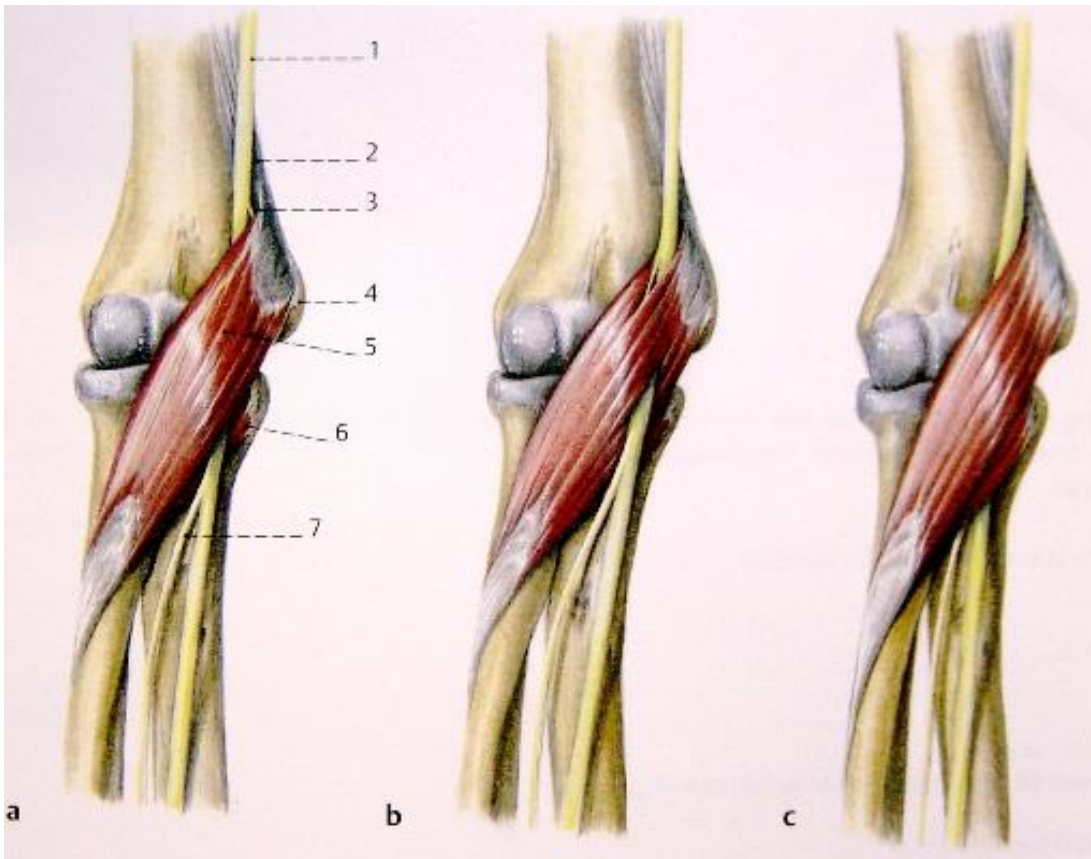
Loss of strength (FDP2)

Scratch collapse test



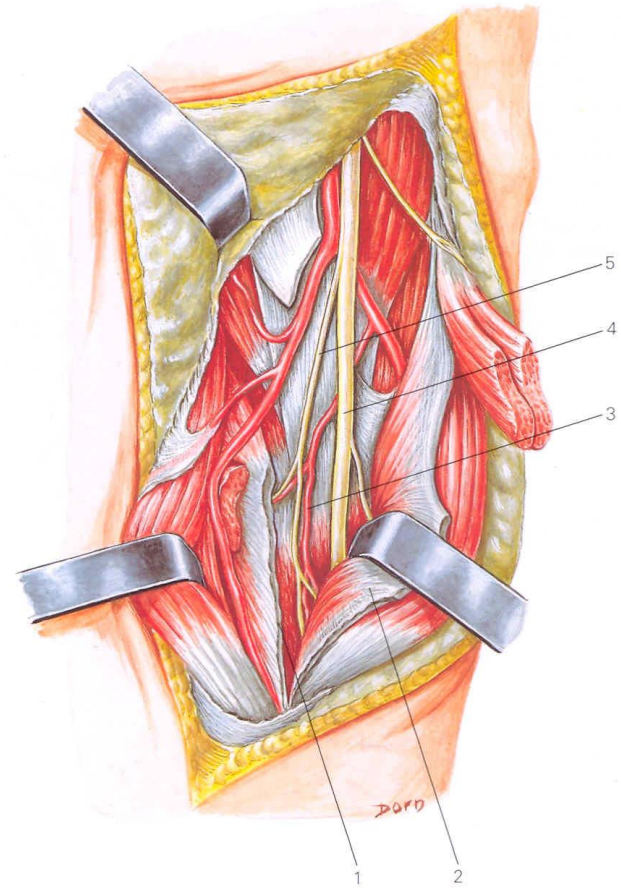
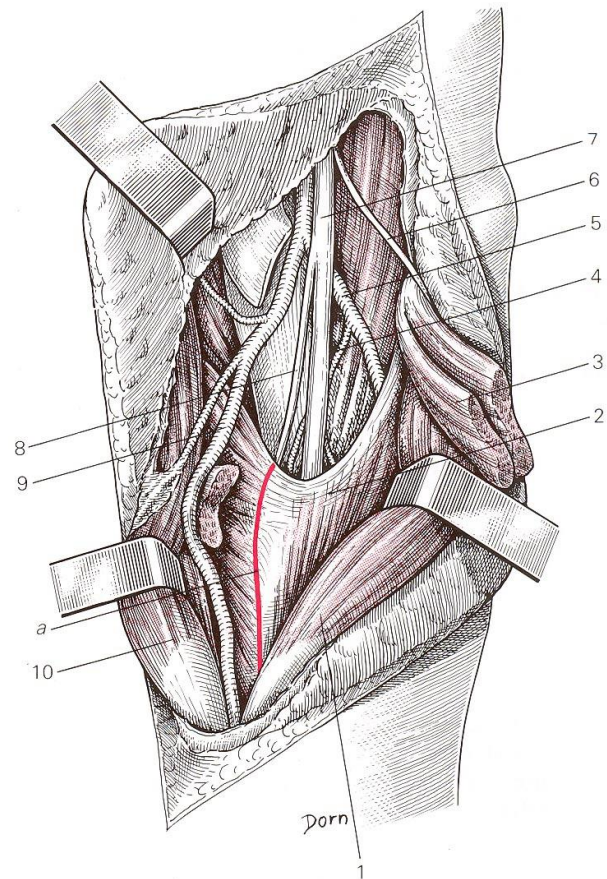


Pronator teres syndrome



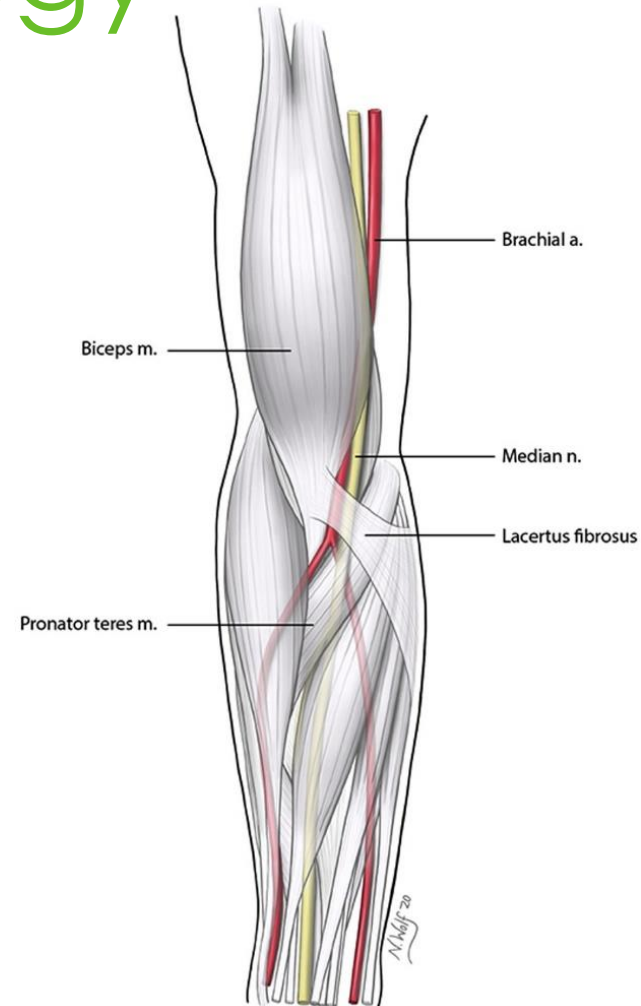
- 74% to 95% between humeral and ulnar head
- Ulnar head absent in 45%, replaced by fibrous structure

PTS - anatomy

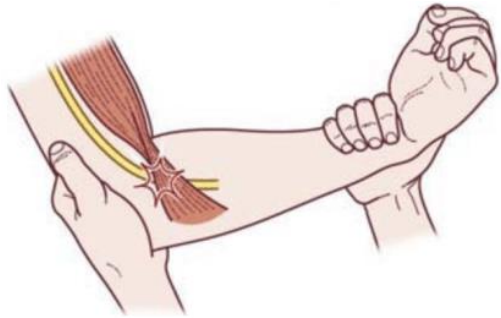

PTS - etiology

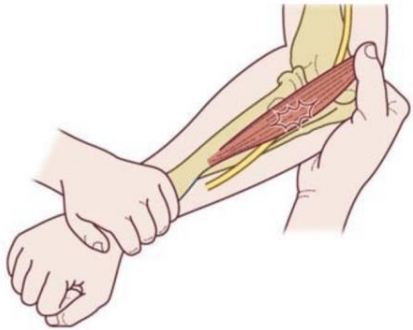
- Traumas
- Masses
- Fibrosis
- Anatomic variations
- Honey-moon-Paralysis
- Double-Crush-Syndrom



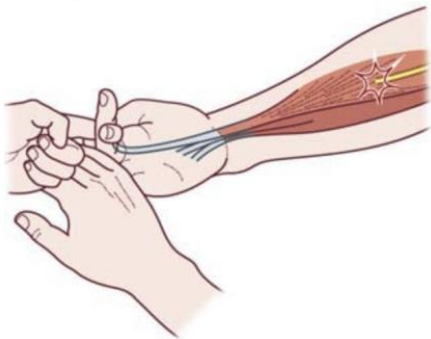
Provocation tests



- Lacertus fibrosus:
Flexion of the elbow and supination of forearm against resistance

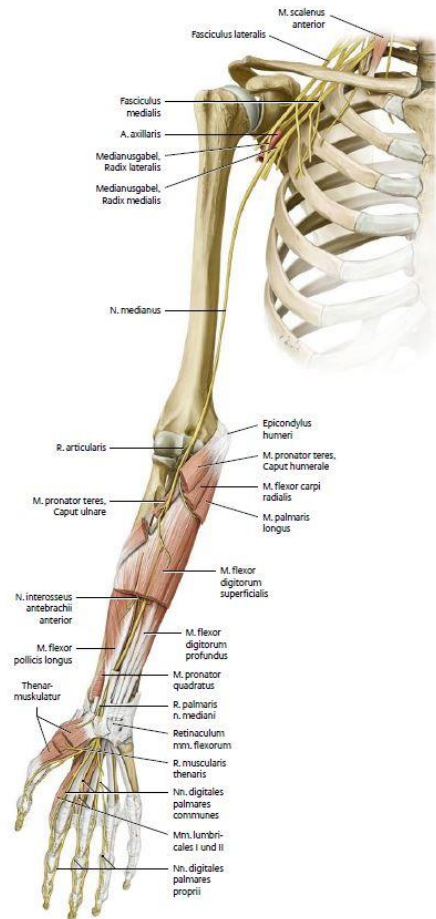


- Pronator teres muscle:
Pronation of the extended forearm against resistance



- FDS-arcade:
Flexion of the middle finger against resistance

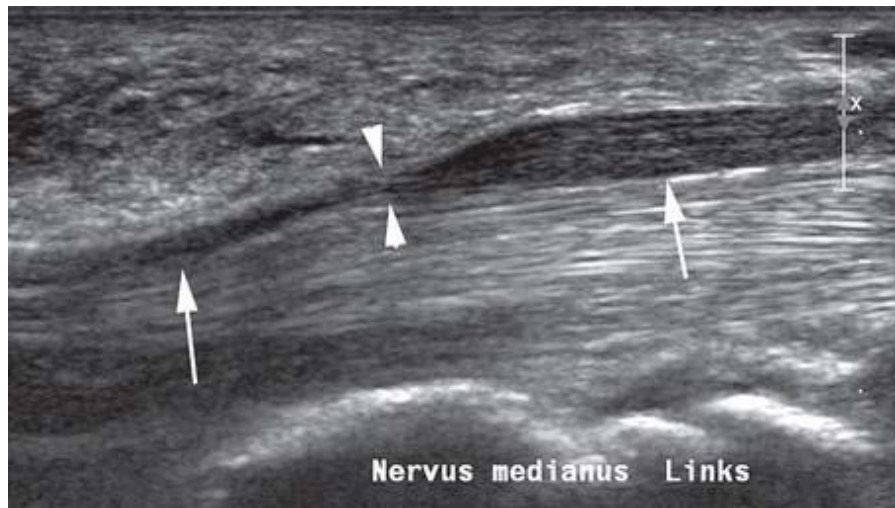
PTS - differential diagnosis



- Cervical disc herniation
- Affection of plexus brachialis
- Neuritis
- Neuropathy / Polyneuropathy
- Focal Dystonia
- **CTS!**

CTS imaging / testing

- X-ray wrist (osteoarthritis, trauma history)
- Sonography



- MRI - tumor?, synovitis?
- Nerve studies:
 - Motor: latency
 - Sensory: velocity

PTS - therapy

Conservative

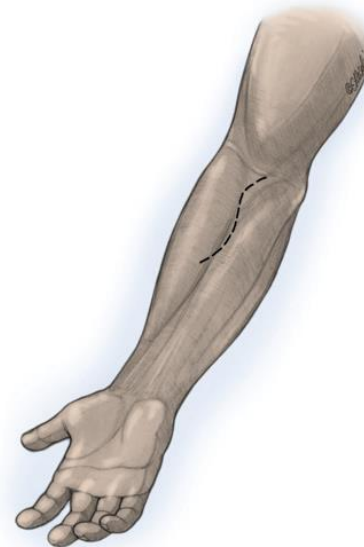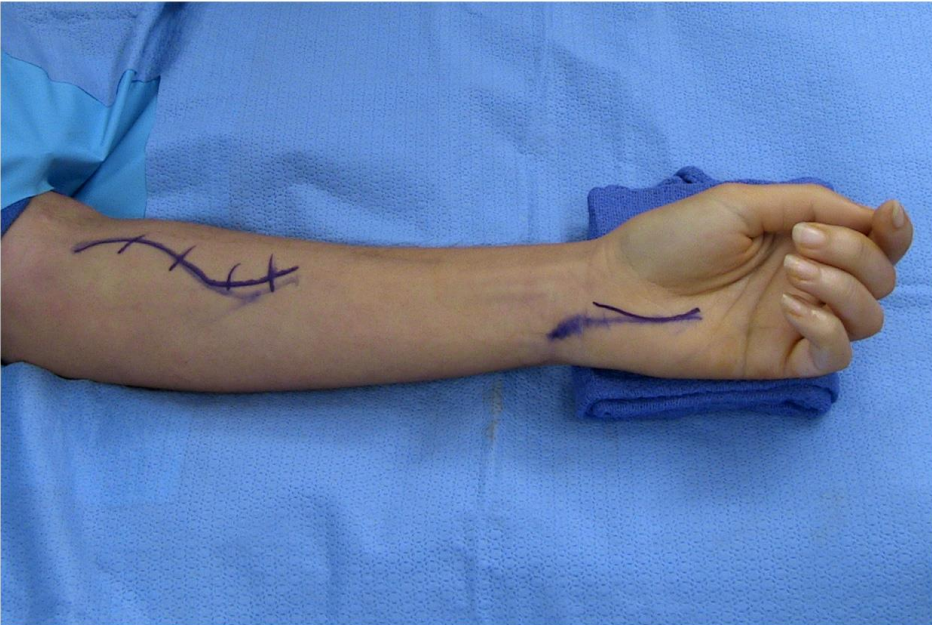
- Brace
 - Median nerve gliding exercises
 - Local cortisone infiltration
 - Antiphlogistics
-
- 50% with spontaneously full regression within 4 months!

Operation

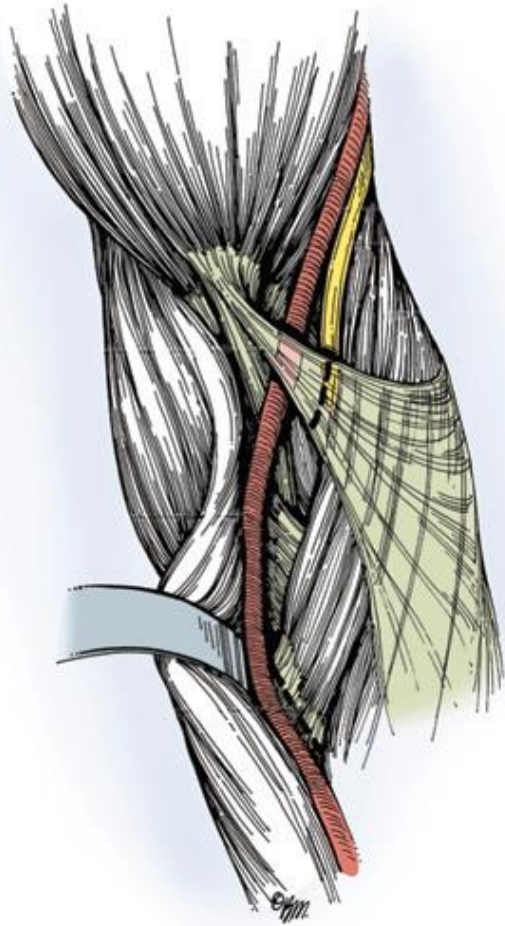
- Lacertus fibrosus?
 - Pronator teres muscle?
 - FDS-arcade?
-
- All together?

Step 1: Approach

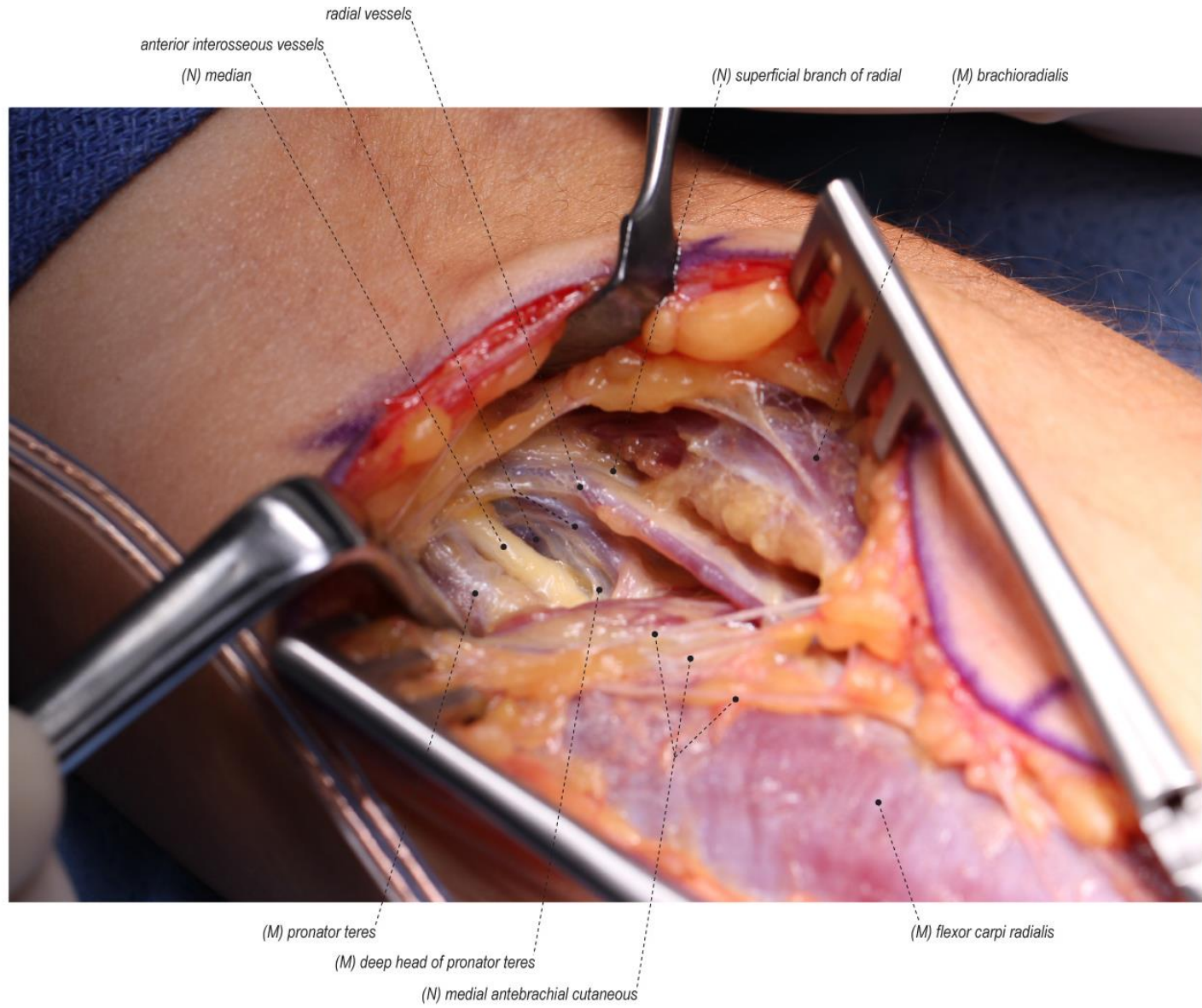
- Lazy -s



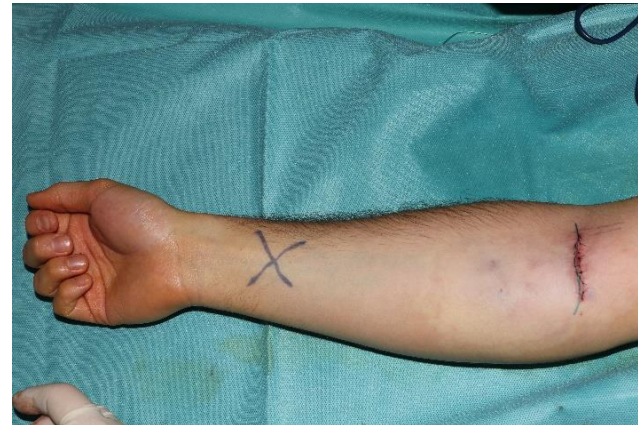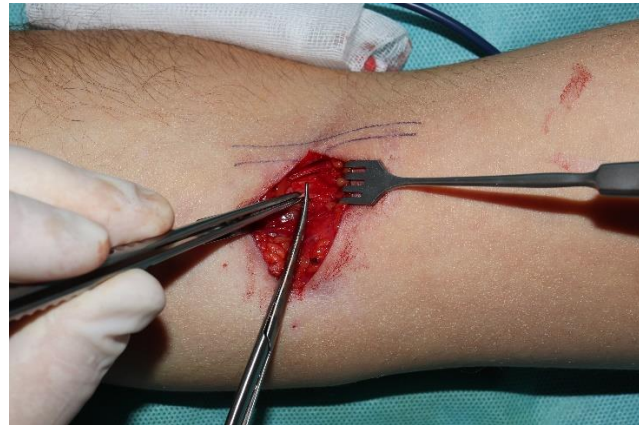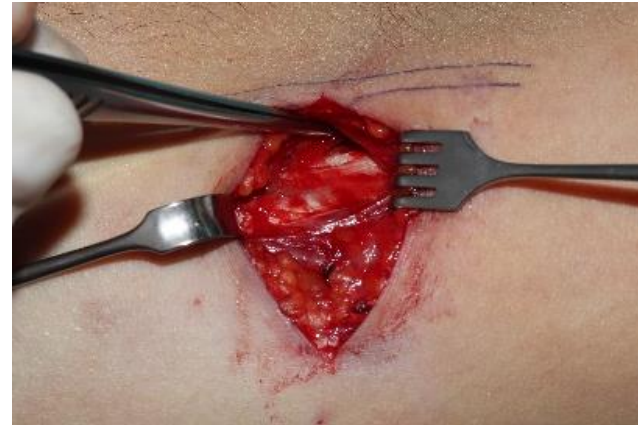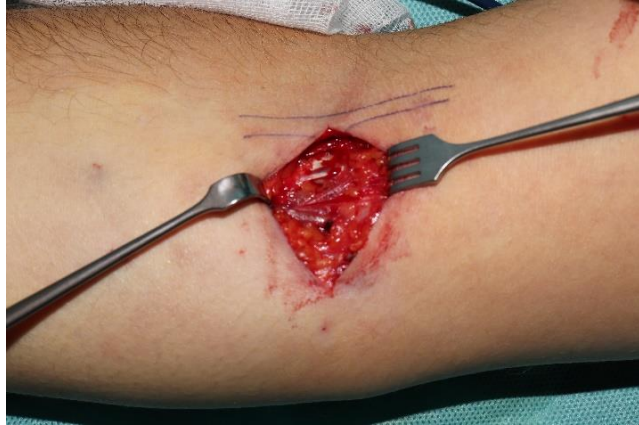Step 2:



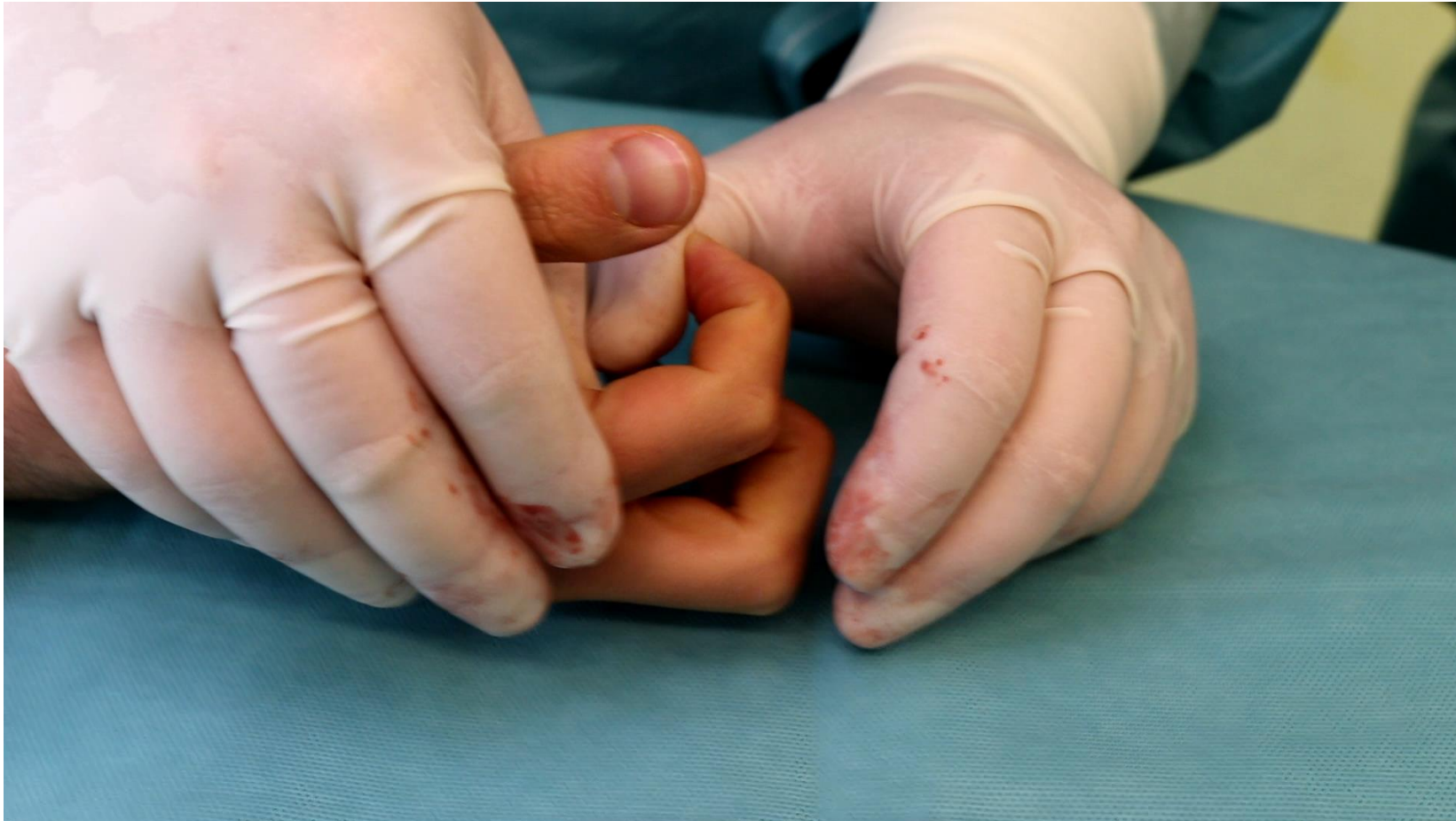- Release of lacertus fibrosus



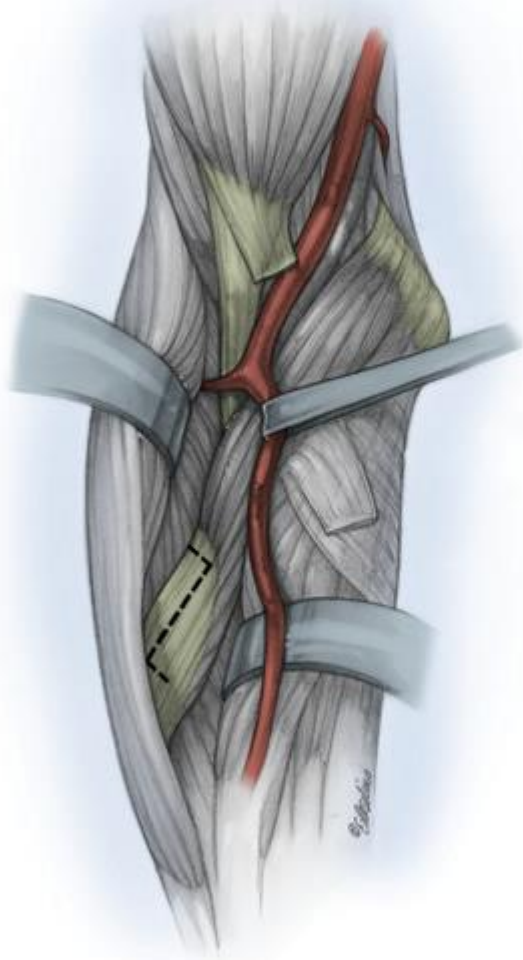
Lacertus Release



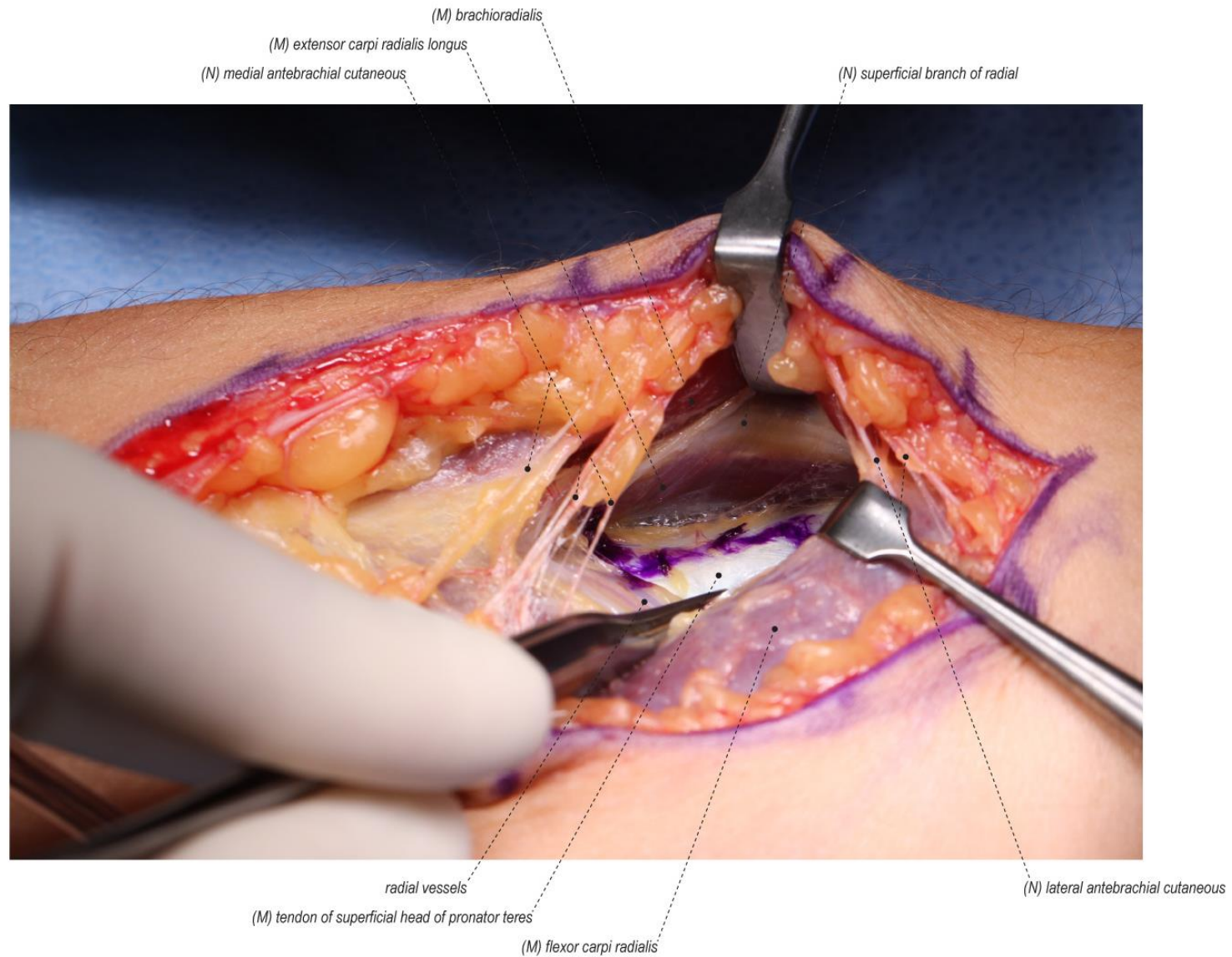
Testing strength of FDP2 after lacertus release

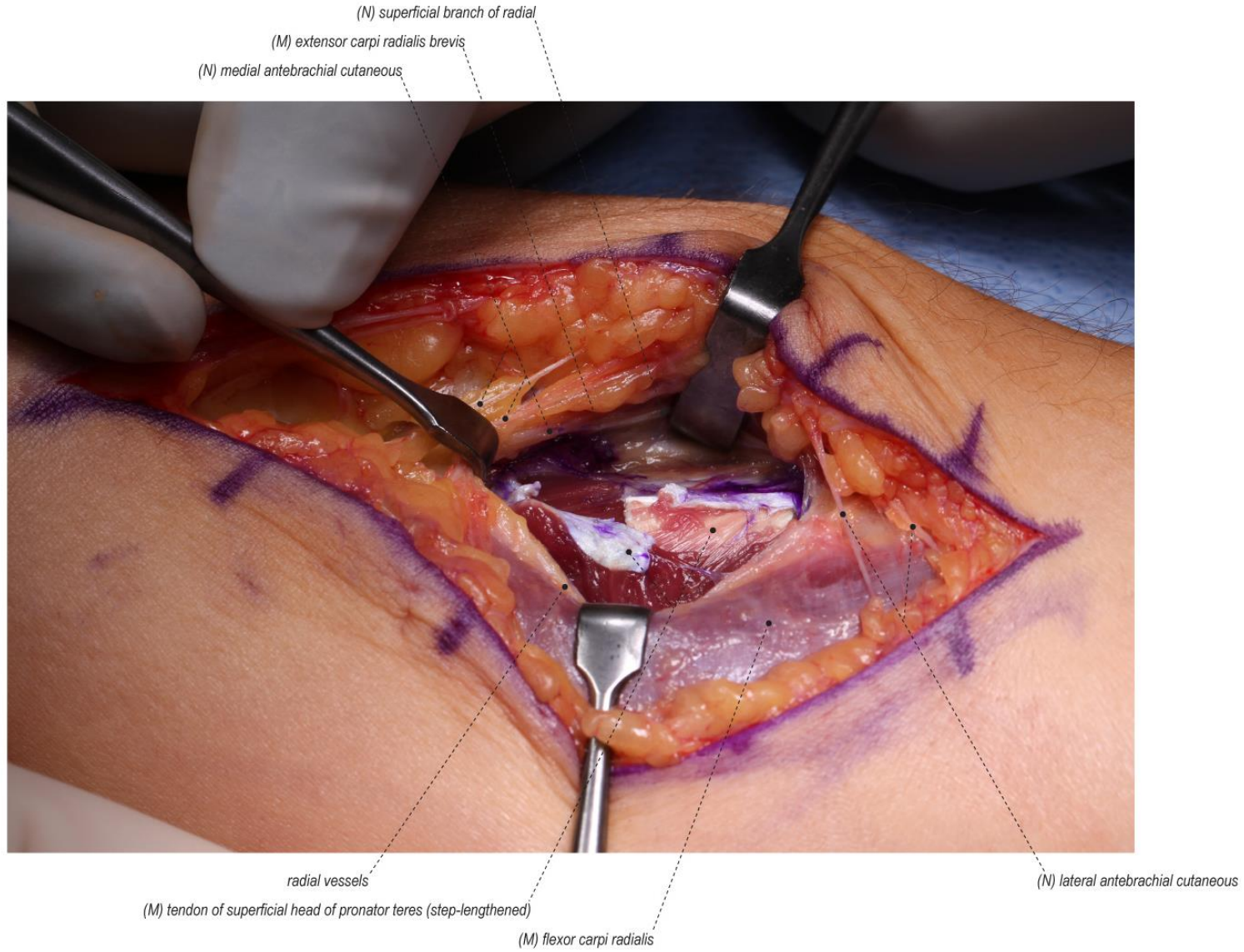


Step 3:

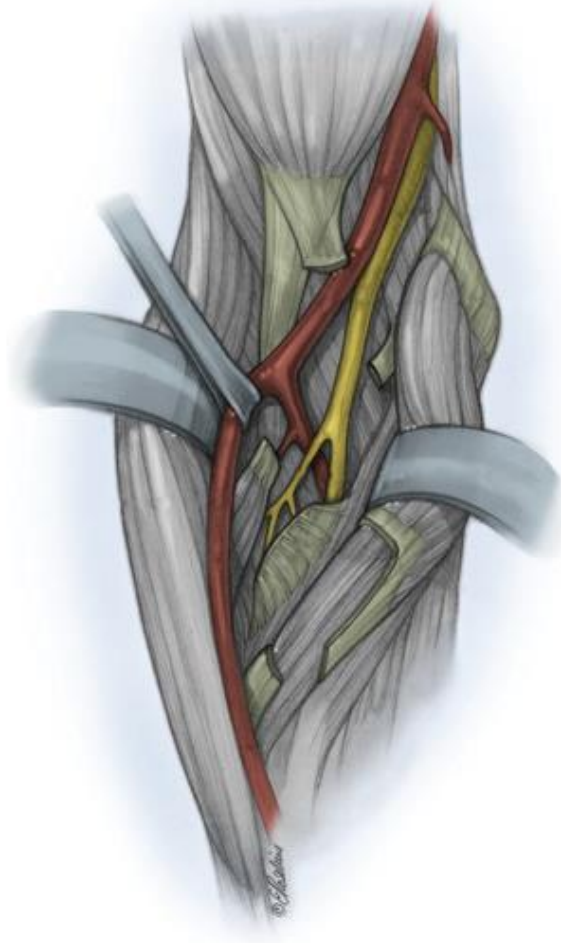


- Step cut of the superficial head

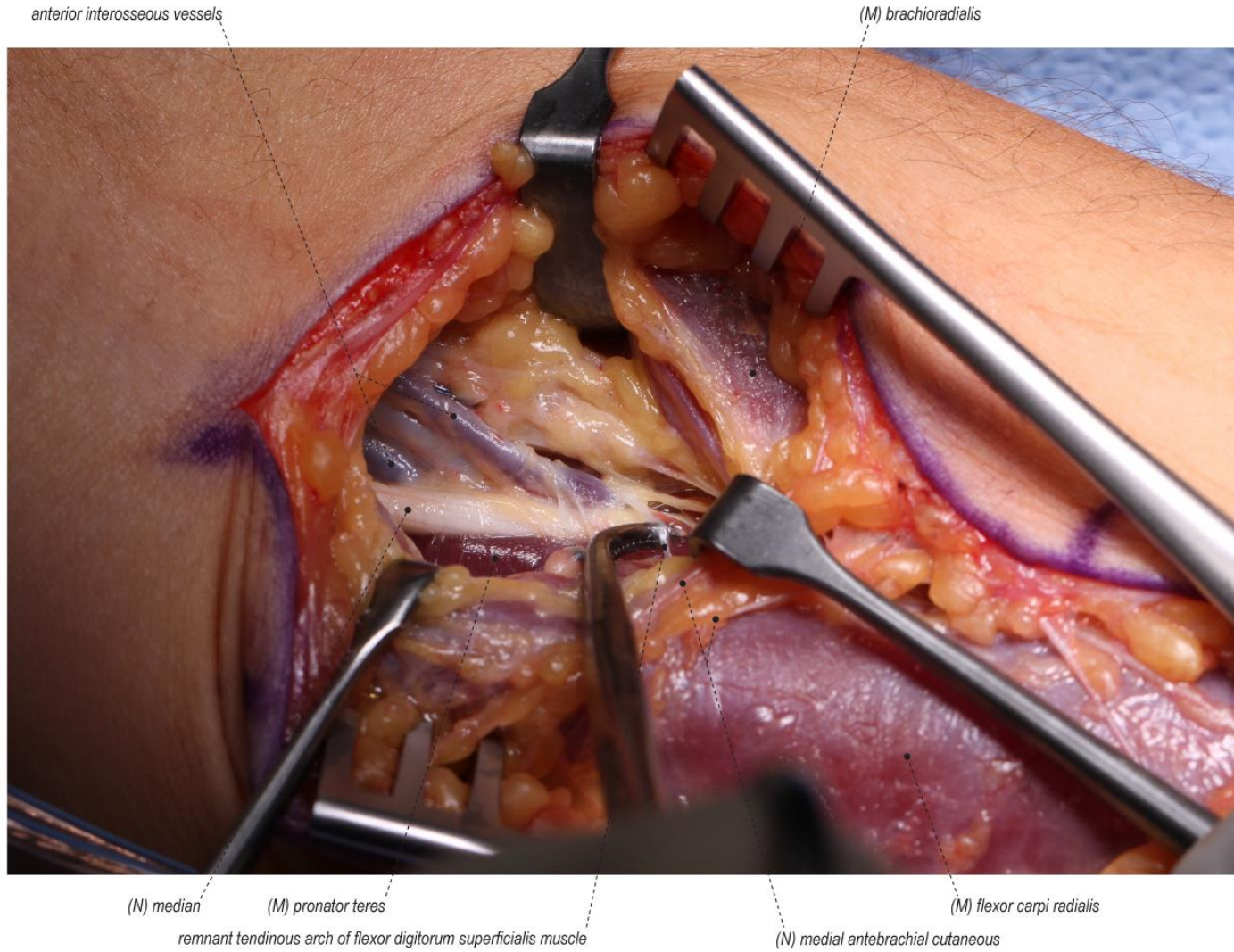


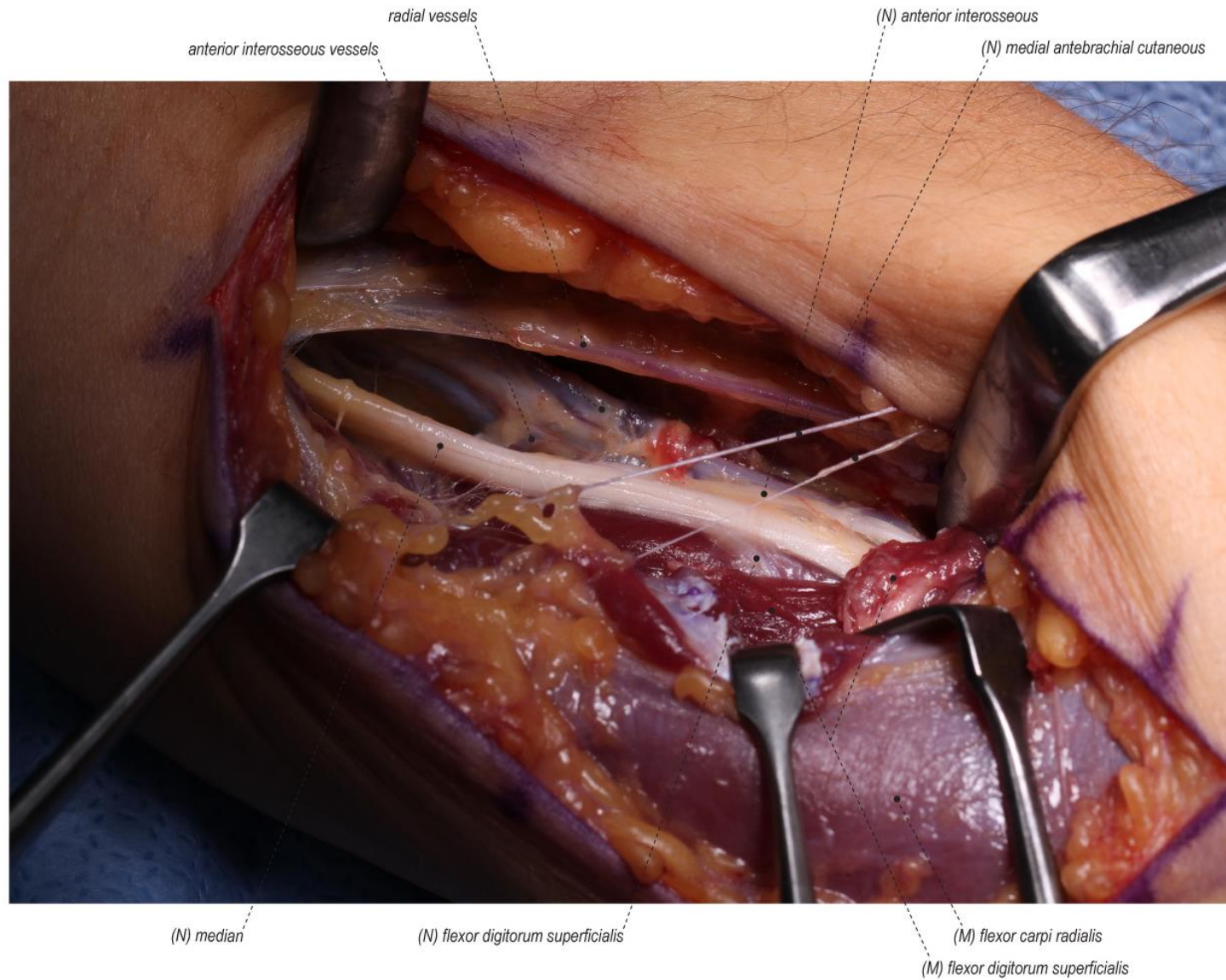


Step 4:



- Excision of the fibrous arch of FDS





Median nerve release in the forearm


Susan Mackinnon



SURGICAL PROCEDURES

Median Nerve Release in the Forearm
Mackinnon SE1, Yee A1

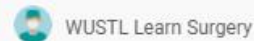Compression neuropathy of the median nerve in the forearm, 2 in the forearm +/- paresthesia/pain in the median nerve territory. While this usually resolves without surgery, acute release. Related anatomical structures include the lacertus flex superficialis, and flexor in the distal arm. Release of the median decompresses the nerve in this area. This release is also a neat. This patient presented with median nerve neuropathy in the forearm release was performed. This video portrays the median proximal exposure, a distal stop lengthening of the superficial flexor can differ from patient to patient, this patient had several tend



7:26

Median Nerve Release in the Forearm - Standard (Feat. Dr. Mackinnon)

16.123 Aufrufe · vor 3 Jahren




Median Nerve Release in the Forearm - Standard Authors: Mackinnon SE1, Yee A1 Published: April 22, 2013 AUTHOR ...

SURGICAL PROCEDURES

Median Nerve Release in the Forearm
Mackinnon SE1, Yee A1

Compression neuropathy of the median nerve in the forearm, 2 in the forearm +/- paresthesia/pain in the median nerve territory. While this usually resolves without surgery, acute release. Related anatomical structures include the lacertus flex superficialis, and flexor in the distal arm. Release of the median decompresses the nerve in this area. This release is also a neat. This patient presented with median nerve neuropathy in the forearm release was performed. This video portrays the median proximal exposure, a distal stop lengthening of the superficial flexor can differ from patient to patient, this patient had several tend



17:07

Median Nerve Release in the Forearm - Extended (Feat. Dr. Mackinnon)

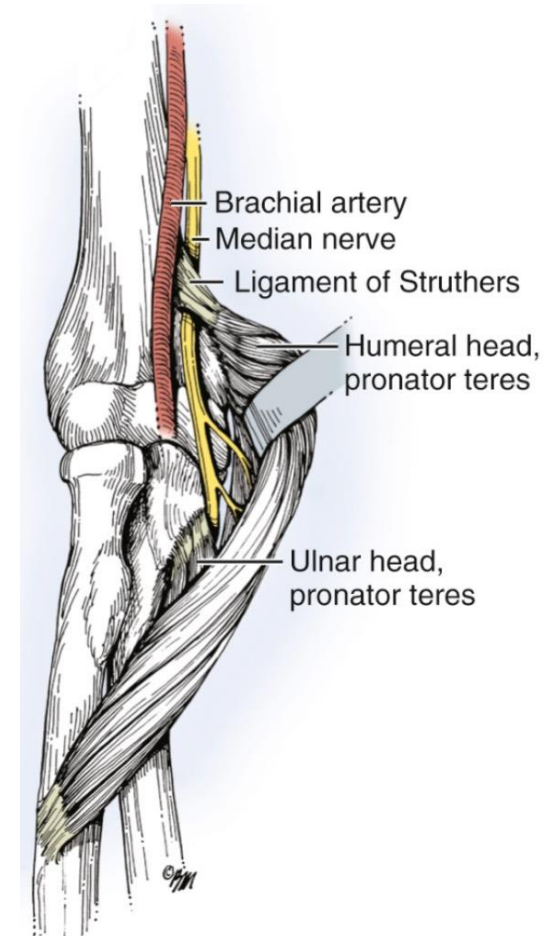
8608 Aufrufe · vor 3 Jahren



Median Nerve Release in the Forearm - Standard Authors: Mackinnon SE1, Yee A1 Published: April 22, 2013 AUTHOR ...

Struthers'-ligament

- In 1-3% of the population, ligment between medial epicondyle and the supracondylar process
- If the Struther ligament is present, median nerve passes behind



Anterior interosseus nerve (AIN) syndrome


Kiloh L, Nevin S : Isolated neuritis of anterior interosseus nerve. Brit med J 1952/1:850-851

Patient history

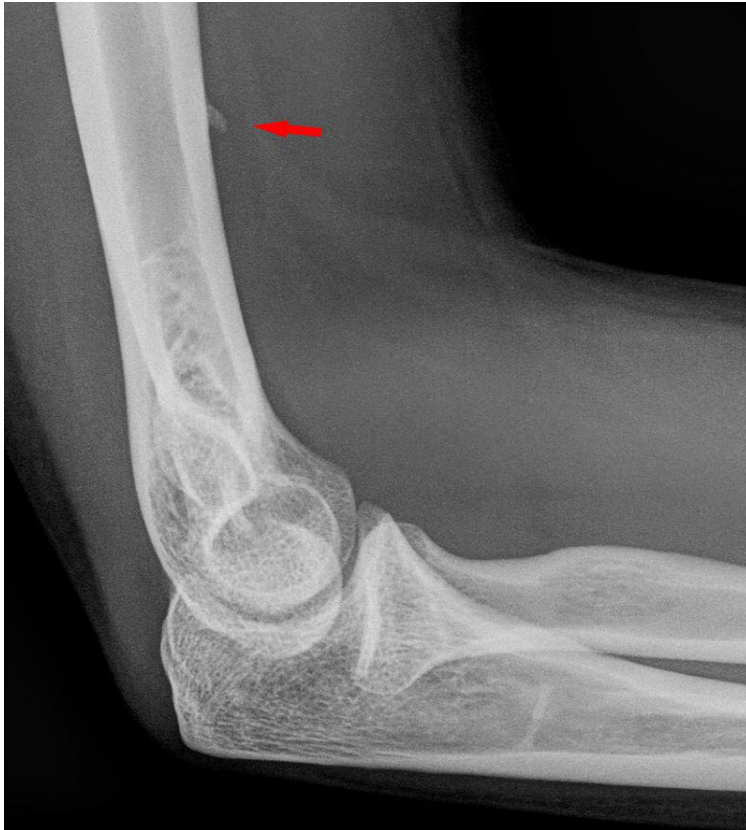- Difficulties of flexion of FPL, FDP2 and FDP3
- Pain

Imaging/testing

- Nerve studies
- MRT



Processus supracondylaris



- Prevalence 1-2%

Thank you for your attention

References

- Wolfe S, Green's Operative Hand Surgery, 7th edition, 2015
- Mackinnon SE, Nerve Surgery, 2015
- Green's Operative Handsurgery 7th Edition, Elsevier Verlag; Wolfe, Scott et al.: 2016
- Die Handchirurgie; Urban&Fischer Elsevier Verlag; Sauerbier, Michael et al.: 2014
- Ultraschalldiagnostik der Hand; Springer Verlag; Kluge, Sebastian: 2015
- Kursbuch Klinische Neurophysiologie; Thieme Verlag; Vogel, Peter: 2011
- Rodner CM, Tinsley BA, O'Malley MP. Pronator syndrome and anterior inter-osseous nerve syndrome. J Am Acad Orthop Surg 2013;21:268–75. [
- Caetano EB, Vieira LA, Almeida TA, Gonzales LAM, Bona JE, Simonatto TM. Bicipital aponeurosis. Anatomical study and clinical implications. Rev Bras Ortop 2018;53:75–81.
- Wynter S, Dissabandara L. A comprehensive review of motor innervation of the hand: variations and clinical significance. Chantelot C, Feugas C, Guillem P, Chapnikoff D, Re´my F, Fontaine C. Innervation of the medial epicondylar muscles: an anatomic study in 50 cases. Surg Radiol Anat 1999;21:165–8. M. Soubeyrand et al. / Hand Surgery and Rehabilitation 39 (2020) 2–1816